



# Long-Term Management of a Refractory Corticosteroid Responsive Tremor Syndrome

Soomin Kim<sup>1</sup>  
Yoonji Kim<sup>1</sup>  
Ji-Hee Kim<sup>1</sup>  
Hyeon-Jin Kim<sup>1</sup>  
Ji-Hye Lee<sup>1,2</sup>  
Migyeong Geum<sup>1,2</sup>  
Ha-Jung Kim<sup>1,2,\*</sup>

<sup>1</sup>Department of Veterinary Internal Medicine, College of Veterinary Medicine, Chonnam National University, Gwangju 61186, Korea

<sup>2</sup>BK21 Project Team, College of Veterinary Medicine, Chonnam National University, Gwangju 61168, Korea

\*Correspondence: kimhj614@jnu.ac.kr

## ORCID

Soomin Kim:  
<https://orcid.org/0000-0002-9419-1412>  
Yoonji Kim:  
<https://orcid.org/0000-0003-0690-2745>  
Ji-Hee Kim:  
<https://orcid.org/0000-0003-0885-8784>  
Hyeon-Jin Kim:  
<https://orcid.org/0000-0003-2751-2201>  
Ji-Hye Lee:  
<https://orcid.org/0000-0002-1548-6598>  
Migyeong Geum:  
<https://orcid.org/0000-0002-3019-4868>  
Ha-Jung Kim:  
<https://orcid.org/0000-0002-2699-0263>

Copyright © The Korean Society of Veterinary Clinics

**Abstract** A 2-year-old intact female Maltese dog was presented with generalized involuntary tremors and nystagmus without regular direction. The dog was conscious the whole time while it was trembling. Its involuntary tremors were alleviated at rest or during sleep. Magnetic resonance imaging (MRI) revealed asymmetric hydrocephalus and caudal occipital malformation. In cerebrospinal fluid (CSF) analysis, a trace of protein was found and total nucleated cell count (TNCC) was slightly increased. However, infectious pathogens were not found. In complete blood count, there was a mild leukocytosis. After the patient received anticonvulsants (midazolam, phenobarbital, KBr), diuretics (furosemide) with an anti-inflammatory drug (prednisolone, 0.5 mg/kg PO bid), and a proton-pump inhibitor (omeprazole), it showed no improvement. The patient was tentatively diagnosed with corticosteroid responsive tremor syndrome. So the anticonvulsants and diuretics were discontinued and the dose of prednisolone was increased to an immunosuppressive dose (1 mg/kg PO bid). After administering the immunosuppressive dose of prednisolone, the patient did not show nystagmus. Its tremors were much alleviated. However, they did not disappear. Five weeks later, the patient showed gradual improvement but still was trembling when moving around. Nine weeks later, its tremors were similar to before. So diazepam (0.3 mg/kg PO sid) was added to the treatment. After that, its tremors were alleviated more. Prednisolone and diazepam were maintained for about five months, with tapering of the dose of prednisolone (until 0.5 mg/kg PO sid). About 7 months later after the treatment was started, the dog was trembling rarely except when it was excited. Therefore, diazepam was discontinued. This case describes a refractory white dog shaker syndrome successfully managed with long-term administration of a steroid and diazepam.

**Key words** corticosteroid responsive tremor syndrome, prednisolone, diazepam, dog.

Received January 11, 2021 / Revised April 12, 2021 / Accepted May 7, 2021



This is an open access article distributed under the terms of the Creative Commons Attribution Non-Commercial License (<http://creativecommons.org/licenses/by-nc/4.0>) which permits unrestricted non-commercial use, distribution, and reproduction in any medium, provided the original work is properly cited.

## Introduction

Corticosteroid responsive tremor syndrome (CRTS), white dog shaker syndrome, is a syndrome showing whole body tremors (6). CRTS is an acquired disorder characterized by acute onset of full-body tremors that are sometimes accompanied by vestibular signs. Underlying causes of this disease are unknown. It is considered as an immune-mediated disease of the cerebellum that might be caused by an imbalance in neurotransmitters (5). CRTS usually occurs in young dogs aged 5 months to 3 years old (7). Sometimes affected dogs might have other neurologic signs such as nystagmus and loss of menace response (1). At first, this disease was identified in white-coated dogs such as West Highland White Terriers and Maltese Terriers. However, recently it has also been reported in breeds of dogs with any color (7). The diagnosis is based on history taking, symptoms, and laboratory exams to rule out other diseases that cause tremors (3,4). Treatment for this disease generally uses corticosteroids and/or diazepam (benzodiazepines) (1,7). In many cases of this disease, tremors can be relieved after an administration of immunosuppressive corticosteroids for a few weeks (1,7). Sometimes their response to therapy is challenging. The present study describes a case of a refractory CRTS successfully managed with glucocorticoids and supportive drugs for a long time.

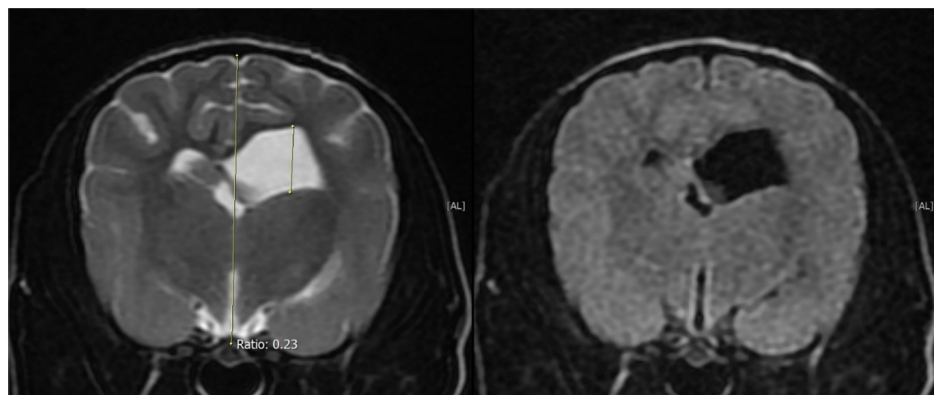
## Case Report

A 2-year-old intact female Maltese was referred to the hospital with generalized tremors and nystagmus. On physical examination, mild tachycardia (142 bpm) and hypertension (150 mmHg) were detected. The patient was alert and responsive. It showed continuous whole-body tremors including four limbs and head. These tremors were involuntary with an acute onset. When sleeping, tremors were alleviated on history taking. The nystagmus was horizontal or rotatory

without a regular direction.

Blood works revealed no remarkable findings except for a mild leukocytosis (18.91 K/ $\mu$ L; reference range 5.05-16.76 K/ $\mu$ L). MRI of the brain was performed to rule out other brain diseases. MRI was obtained with a 1.5 Tesla TOSHIBA Exerlart Vantage (TOSHIBA, Tokyo, Japan). In the transverse image, a left lateral ventricle was asymmetrically enlarged. The Ventricle to Brain Height Ratio (VBHR) was 23%. Therefore, the patient was diagnosed with hydrocephalus (Fig. 1). In the sagittal image, caudal occipital malformation and occipital dysplasia were also found. However, these findings might be little relevance to clinical signs. Cerebrospinal fluid (CSF) was examined with a dipstick. A trace of protein and glucose were found. Total nucleated cell count (TNCC) was slightly increased (11 / reference 0-5). Other results of CSF analysis were not remarkable. Viruses and other organism including protozoa (*Cryptococcus* spp., *Bartonella*, *Histoplasma*, *Blastomyces*, *Anaplasma*, *Ehrlichia*, *Neospora* spp., Lyme, *Toxoplasma gondii*, and Distemper) were also ruled out by real-time PCR (Korea Vet Lab, Seongnam, Gyeonggi-do, Korea).

Based on several test results, firstly the relationship between the hydrocephalus and tremors should be considered. At first, midazolam (0.2 mg/kg IV; Midazolam inj., Bukwang, Seoul, Korea), phenobarbital (3 mg/kg IV bid; Phenobarbital Injection, Jeil Pharm, Daegu, Korea), furosemide (1 mg/kg IV; Lasix injection, Handok Pharm, Seoul, Korea), omeprazole (1 mg/kg PO sid; OMP<sup>®</sup> tab, CKD Pharm, Seoul, Korea), and prednisolone (0.5 mg/kg PO bid; Solondo<sup>®</sup>; Yuhan, Seoul, Korea) were used for treating its hydrocephalus. However, there was no response. Then KBr (100 mg/kg PO; Potassium bromide, Daejung, Siheung, Korea) was added to the treatment. After one day, still there was no response to the treatment. Therefore, the tentative diagnosis was considered as CRTS. Immunosuppressive levels of prednisolone (1 mg/kg PO bid; Solondo<sup>®</sup>; Yuhan, Seoul, Korea) were given to the patient and anticonvulsants and diuretics were discontinued.



**Fig. 1.** Transverse image of MRI of the brain. The left ventricle of the brain was enlarged. VBHR: 23%.

One week later, tremors were improved at rest. Its nystagmus also disappeared. Five weeks later, the tremors were more alleviated than before. So the dose of prednisolone was tapered (1 mg/kg PO sid). After about two months, its improvement of clinical signs seemed to be correlated with the use of the steroid only. Thus, drugs for treating hydrocephalus (omeprazole) were removed.

Nine weeks later, the dose of prednisolone was tapered (0.5 mg/kg PO sid) and diazepam (0.3 mg/kg PO sid; Valium Tab, Roche, Seoul, Korea) was added to the treatment because its tremors showed no more improvement. Its tremors were slightly alleviated after the addition of diazepam but not completely improved. Thus, 17 weeks later, the dosage of diazepam was increased (0.3 mg/kg PO bid). After four weeks, its tremors showed subtle improvement. Therefore, the dosage of diazepam was gradually tapered and discontinued. After 29 weeks using only prednisolone (0.5 mg/kg PO sid), the patient was not trembling except when it was excited. The patient was sent back to a local hospital. The hospital was ordered to manage the patient and taper off the prednisolone according to the patient's condition. At the 3-month follow-up the conditions, the patient was doing well without any recurrence and prednisolone was discontinued.

## Discussion

CRTS is an idiopathic generalized tremor. To be diagnosed with this, other causes of tremors should be ruled out. The patient in the present case had no history of eating any toxic substances. Hydrocephalus, caudal occipital malformation, and occipital dysplasia were found in MRI. However, there was no hemorrhage or inflammation of the brain in MRI. Infectious pathogens were not found in CSF analysis either. At first, the patient received anticonvulsants and diuretics without showing a response to treatment. The treatment was then changed to an immunosuppressive dose of prednisolone, leading to a response to the treatment with prednisolone. Based on these results, the patient was tentatively diagnosed with CRTS.

MRI imaging of dogs with CRTS is usually normal. However, in the present case, asymmetrical hydrocephalus, caudal occipital malformation, and occipital dysplasia were found. Caudal occipital malformation syndrome (COMS) is a canine analog of human Chiari type 1 malformation. This syndrome can lead to abnormalities of CSF flow with appearance of hydrocephalus and syringomyelia at the same time. Clinical signs of COMS are associated with concurrent diseases such as hydrocephalus or syringomyelia (2). However, these find-

ings may not be direct causes of tremors.

For treating CRTS, an immunosuppressive dose of steroid can be used and diazepam can be added to the treatment (1,4,7). In a case report, a patient was treated with an immunosuppressive dose of steroid prednisolone at 2 mg/kg PO bid (4). In another case report, the patient received an immunosuppressive dose of steroid prednisolone at 2 mg/kg PO sid with diazepam at 1 mg/kg PO tid (7). Tremors disappeared at about 5 days in these two case reports. Steroids and diazepam were also used in two cats with idiopathic generalized tremor syndrome, similar to CRTS (5). One cat was treated and its tremor relapsed but disappeared after 6 months while another cat was normalized one week later (5). Based on these reports, clinical outcome is variable.

The patient in the present case received a steroid with dose gradually tapered and diazepam for the treatment. The dose of prednisolone was started at 1 mg/kg bid. It was then tapered gradually to 0.5 mg/kg sid. Diazepam was started at 0.3 mg/kg bid dose. It was then tapered. The treatment duration until the patient was normalized was about 7 months. In this case, the improvement of tremors was slow compared to that in other cases. The difference between this case and other cases is whether or not there is a congenital deformity of the brain. Response of the treatment might be related to the presence of a congenital disease.

## Conclusions

This case report describes a Maltese dog with congenital brain deformities affected by refractory CRTS. In most cases, the treatment period was much shorter than this case when patients did not have congenital brain deformities. The relation between congenital brain deformities and treatment duration of CRTS has not been studied yet. However, this case suggests the possibility of such relation.

## Acknowledgements

This research was supported by the Basic Science Research Program through the National Research Foundation of Korea (NRF), funded by the Ministry of Education (NRF-2020R1A2C2005364).

## Conflicts of Interest

The authors declared no potential conflicts of interest with respect to the research, authorship, and/or publication of this article.

## References

1. Bagley RS. Tremor syndromes in dogs: diagnosis and treatment. *J Small Anim Pract* 1991; 33: 485-490.
2. Dewey CW, Berg JM, Stefanacci JD, Barone G, Marino DJ. Caudal occipital malformation syndrome in dogs. *Compend Contin Educ Pract Vet* 2004; 26: 886-896.
3. de Freitas DM, Alves LC, Rosado IR, Alves EGL. Corticosteroid responsive tremor syndrome associated with estrus in a female dog. *Acta Sci Vet* 2019; 47: 382.
4. Kang BT, Jung DI, Park C, Kim JW, Kim HJ, Lim CY, et al. Steroid responsive tremor syndrome in a maltese dog. *J Vet Clin* 2006; 23: 337-339.
5. Mauler DA, Van Soens I, Bhatti SF, Cornelis I, Martlé VA, Van Ham LM. Idiopathic generalised tremor syndrome in two cats. *J Feline Med Surg* 2014; 16: 378-380.
6. Wagner SO, Podell M, Fenner WR. Generalized tremors in dogs: 24 cases (1984-1995). *J Am Vet Med Assoc* 1997; 211: 731-735.
7. Yamaya Y, Iwakami E, Goto M, Koie H, Watari T, Tanaka S, et al. A case of shaker dog disease in a miniature dachshund. *J Vet Med Sci* 2004; 66: 1159-1160.